



**PATIENT**

Bohdi Collins

**SPECIES**

Canine

**BREED**

Miniature Pincher

**SEX**

Male Neutered

**AGE**

12 years

**WEIGHT**

15.9lbs

**INTERPRETED BY**

Maggie Machen Lamy,  
DVM, DACVIM  
(Cardiology)

**IMAGING PERFORMED BY**

C. Belan, DVM

**HOSPITAL NAME**

Beddington Trail  
Animal Clinic

**REFERRING VET**

Dr. Bahadur

**INVOICE**

26417

**DATE**

9/16/22

**PRESENTING CLINICAL SIGNS**

History: Recheck echo.

-Current medications: Pimobendan 1.25mg SID.

-Pertinent previous echo findings (2/2022 MML): Mild MR, mild LAE, no LVE, mild TR: 2.8m/s. LA: 2.3, LV: 3.8.

**ECHOCARDIOGRAM FINDINGS**

2D, m-mode, color flow and doppler imaging is available. Diffuse thickening of mitral valve leaflets with mild prolapse into the left atrial lumen. Moderate eccentric mitral regurgitation with moderate left atrial dilation. Normal MR velocity. Mild LV dilation with adequate myocardial function. The tricuspid valve appears normal with mild tricuspid regurgitation. Velocity consistent with early pulmonary hypertension. Normal right atrial and ventricular diameter and morphology. The pulmonic and aortic valves are normal in morphology and mobility. Normal pulmonic and aortic outflow velocities with laminar flow. No obvious aortic or pulmonic insufficiency. No pericardial or pleural effusion noted. No obvious cardiac masses.

**CARDIAC CHART**

CANINE CARDIAC PARAMETERS	MR VMAX (m/s)	TR VMAX (m/s)	LA/AO (Boon method)	LA/AO (Heart Base; Swe)	FS (%)	EF (%)	EPSS (cm)
NORMAL PARAMETER	4.5-5.5	<2.7	1.3	<1.6	28-40	40-100	<0.6
PATIENT	6.3	3.0	1.78	1.8	34	60	0.5
CANINE CARDIAC PARAMETERS	HR (BPM)	AV VMAX (m/s)	PV MAX (m/s)	BODY WEIGHT (kg)	LA 2D short axis Base view (cm)	LVIDd Avg; 2D and m-mode short axis (cm)	LVIDs Avg; 2D and m-mode short axis (cm)
NORMAL PARAMETER	50-100	0.7-1.7	0.7-1.6	BELOW	BELOW	BELOW	BELOW
PATIENT	65	2.5	1.2	7.2	2.3	4.1	2.7
*Normal chamber parameters expressed as a mean value (SD)				3	1.27 (5.3)	2.46 (2.46)	1.36 (5.5)
<b>BODY WEIGHT DEPENDENT PARAMETERS</b>				5	1.40 (4.5)	2.74 (5.2)	1.60 (4.7)
<i>*Note: All measurements based upon multi-modal images and methods. An average value is reported.</i>				10	1.50 (3.8)	3.27 (3.5)	2.06 (3.1)
				15	1.83 (2.0)	3.71 (2.4)	2.43 (2.1)
				20	2.02 (1.9)	4.14 (2.2)	2.80 (2.0)
				25	2.18 (2.4)	4.48 (2.9)	3.10 (2.5)
				30	2.33 (3.3)	4.83 (3.9)	3.39 (3.4)
				35	2.48 (4.3)	5.17 (5.0)	3.69 (4.5)
				40	2.62 (5.2)	5.48 (6.1)	3.96 (5.4)
				50	2.88 (7.1)	6.07 (8.3)	4.46 (7.4)

**INTERPRETATION OF THE FINDINGS & FURTHER RECOMMENDATIONS**

Chronic degenerative valve disease persists with evidence of progression. Previously mild MR has advanced to moderate, with increasing left heart dimensions. The tricuspid leak is stable. Early pulmonary hypertension is noted, which is of unknown significance in an asymptomatic dog. Moderate left atrial enlargement indicates there is relatively low risk for imminent complication, however risk for progression to spontaneous congestive heart failure in the future is elevated.



**PATIENT**

Bohdi Collins

Based upon these findings, continue Pimobendan is recommended at **twice daily dosing**. Additionally, a baseline BP is recommended. Continued assessment of progression is recommended, with a guarded prognosis going forward (stage B2). Patient may be at risk for development of CHF, arrhythmias, and/or sudden death going forward.

**SPECIES**

Canine

Omega fatty acid supplementation and mild salt restriction may also be of some long-term benefit. Monitor for development of a progressive cough, labored breathing, exercise intolerance or collapse episodes.

**BREED**

Miniature Pincher

Anesthetic risk remains mildly elevated. Cardiac protective drug choices (opioid/benzodiazepine premedication, Propofol or alfaxalone induction, iso or sevo gas) are recommended. Monitor for arrhythmias, hypotension, and hypoxia both intra and post-operatively and intervene as necessary. Judicious IV fluid rates are recommended to avoid fluid overload. Avoid heart rate stimulating drugs such as atropine unless clinically indicated.

**SEX**

Male Neutered

**AGE**

12 years

**PLAN**

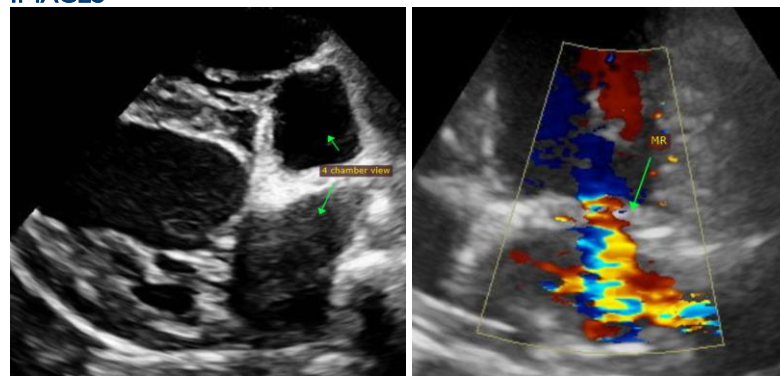
Baseline BP recommended every 6 months. Continue Pimobendan 0.3mg/kg PO **q12h**.

Recommend monitor for progression with a recheck echocardiogram in 6 months, sooner if any development of clinical signs.

**WEIGHT**

15.9lbs

**IMAGES**



**INTERPRETED BY**

Maggie Machen Lamy,  
DVM, DACVIM  
(Cardiology)

**IMAGING PERFORMED BY**

C. Belan, DVM

**HOSPITAL NAME**

Beddington Trail  
Animal Clinic

The information and recommendations provided are based on the images presented by the referring veterinarian. No evaluation can be communicated regarding pathology that was not visible in the image/video clips provided.

**REFERRING VET**

Dr. Bahadur

Thank you for this referral. This report was generated using transcription software, and minor dictation errors may be present. If the clinical or image interpretation does not parallel your findings or if I can be of any further assistance, please contact me.

**INVOICE**

26417

**Maggie Machen Lamy, DVM**

**Diplomate of the American College of Veterinary Internal Medicine (Cardiology)**

info@sonopath.com

**DATE**

9/16/22